A histological study of the efficacy of active biomass EM-X in protecting kidney tissue from the effect of ultraviolet (UV) rays in white rats

Ahmed Hamid Ahmed
Department of Pathological Analysis, College of Applied Science, University of Samarra, Iraq
ahmed.hamed@uosamarra.edu.iq

Abstract
This study aimed to investigate the histological effect on the kidneys of albino rats orally dosed with an effective biomass solution (EM) exposed to ultraviolet (UVC) rays at a wavelength of 275 - 265 nm. It was divided into three groups for each group (5) male rats. The first group was exposed to ultraviolet rays of the mentioned wavelength for half an hour on a daily basis, and the second group was exposed to the same rays for the same time and were orally dosed with an effective biomass solution (produced by the Japanese company Amero) daily for three weeks. While the control group was not exposed or dosed, the animals were killed and dissected, and a portion of rat kidneys were taken to prepare for histological study under a light microscope and to diagnose the histological changes occurring in the renal tissue.

1. Introduction

Ultraviolet rays are divided into three types of UVA rays that are most common on the Earth's surface all year round, and are characterized by their ability to penetrate deep into the human skin, damaging connective tissue cells, leading to premature aging, deep wrinkles, the risk of photosensitivity, and various forms of cancer. Skin. UVB rays are less intense, and their penetration into the skin is less deep compared to ultraviolet (UVA) rays, and they are responsible for burning the skin. UVC rays: It is considered the most dangerous to humans, animals and plants among the types of ultraviolet rays. It does not penetrate the Earth's surface thanks to the ozone layer, but as a result of the pollution factors that led to the damage of the ozone layer, these rays are penetrated through the atmosphere and thus more damage The dangers to life above the earth's surface [1،2].

The most important natural factor for protection from ultraviolet rays is the ozone layer (O3), which is one of the layers of the atmosphere, which works to prevent the arrival of harmful ultraviolet rays to living organisms, but due to the increasing air pollution in recent decades, this layer has eroded, which led to the arrival of a high percentage of Ultraviolet rays to the surface of the earth and the emergence of distorting, mutagenic and cancerous effects on living organisms [3]. The kidneys are located behind the parietal pleura and on both sides of the spine. There is a concavity on the inner surface of the kidney called the hilum, which is the place of entry and exit of the renal blood vessels and ureters. The kidney consists of an outer part called the cortex and an inner part called the pulp. The last appears to be made up of a number of three-faceted structures with shapes hierarchical filled pulp.

The apical part of the pyramid, which is called the renal nipple, is surrounded by a funnel shape called the renal pelvis or calyx, which is an extension of the ureter. As for the broad base of the pyramid, it is immersed in the cortex layer, which in turn pushes between each of the two adjacent pyramids, forming what is known as the renal columns.

The building unit of the kidneys is known as the nephrone. The nephron consists of Bowman's capsule, and the second component of the nephron is the proximal convoluted tubule, which is characterized by many torsions and is located in the cortex, and the loop of Henley is the third component of the nephron, which is in the shape of a letter and then the distal convoluted tubule Distal convoluted tubule, which is the last part of the nephron [5,4] Active biomass, which is a

natural preparation widely spread in East Asia, especially in Japan [6], which is produced by fermenting papaya plant, extract of seaweed and unpolished rice, and it contains a compatible group of beneficial microorganisms including photosynthetic bacteria, And lactic acid bacteria, and yeasts as in [8,7] that all microorganisms used in the production of effective biomass EM were classified under the standard (safety first class) and every food item that is classified under the first safety standard is of the types that do not cause any kind.

This classification has been adopted by the American Public Health Association after undergoing hazardous tests. also approved by the Scientific Advisory Committee for the Measurement of Microorganisms in the United States of America, as all types of acidophilus and yeast used in active biomass products (EM) are included in the American classification list of the United States Food and Drug Administration, one of the agencies of the US Public Health Administration and are recognized on the basis of their safety and freedom from risks that harm human health and the safety of the environment.[9,6]

2. Materials and methods:

Preparing the animals: 15 animals of white male Rattusrattus were used in this study, their ages ranged between 12-10 weeks, obtained from the animal house in the pharmacology department of the Samarra Pharmaceutical and Medical Appliances Industry Company. The animals were divided into three groups and placed in specialized cages. The appropriate laboratory conditions were created for them, such as ventilation and a temperature ranging between 26-24 °C and a 12:12 hour lighting system, light to dark, except for the exposure period. Rats were given water and a concentrated diet, and the rats were left to acclimatize for at least a week before the start of the experiment. Care continued in the cleanliness and sterilization of cages. With 70% ethanol alcohol disinfectant once a week.

Experiment groups:

• The first group (G1) was exposed daily to ultraviolet rays for a period of three weeks and for half an hour [10].

• The second group (G2) was exposed daily to ultraviolet rays for a period of three weeks for half an hour and was orally dosed with effective biomass solution EM at a dose of 3 ml / kg of body weight [11].

• The control group (G3) was not given a solution and was not exposed to radiation.

microscopic preparation

After the exposure period ended and the animals were dosed, the animals were killed and dissected and the kidney was taken, which was fixed with formalin saline solution, then water was withdrawn from it and the models were polished using xylene. (5) micrometers, then loaded onto glass slides, and stained with hematoxylin and eosin [12].

Results: Histological changes in the kidneys of laboratory rats:

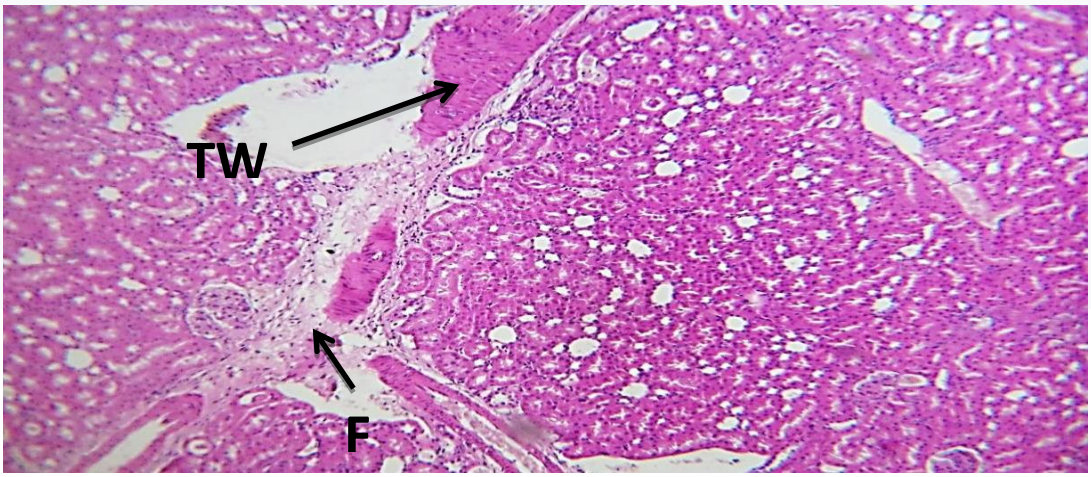

Figure 1: A cross section of the kidney of laboratory rats, group I (G1) exposed to ultraviolet rays, showing thickening of the thickening wall (TW) of blood vessels with fibrocytes (F) stained with hematoxylin and eosin H&E (X100)

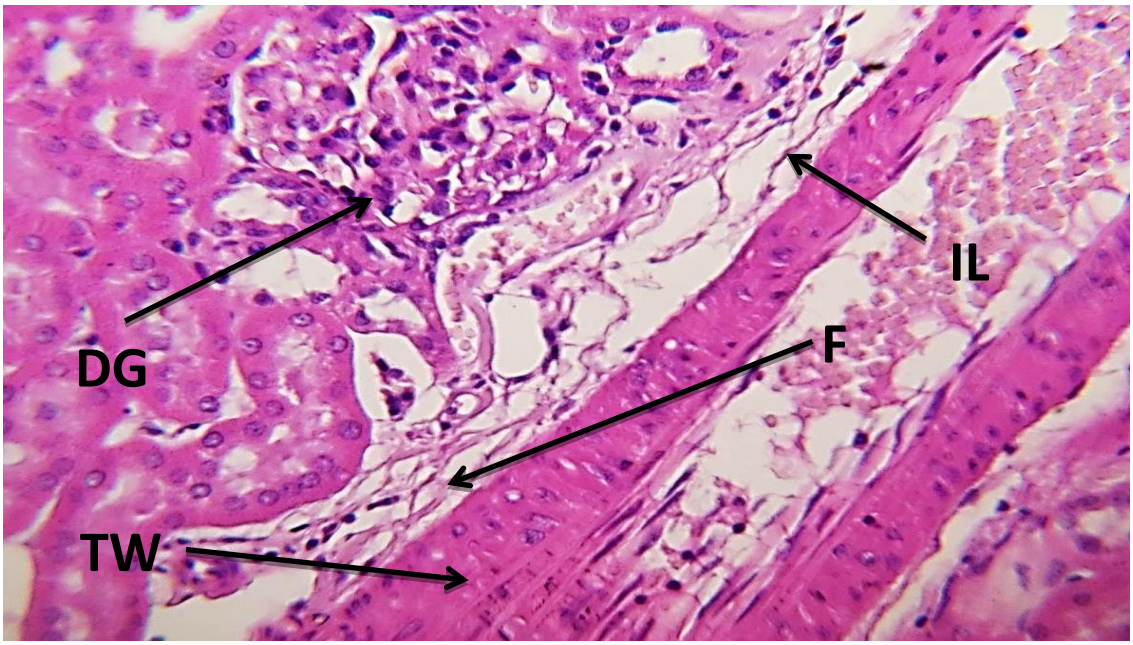

Figure 2: Cross-section of the kidney of laboratory rats Group I (G1) exposed to UV radiation showing damage glomerulus (DG), vascular thickening (TW), infiltration of lymphocytes (IL), and fibroblast pooling (F) H&E Hematoxylin&Iosin Color (X100)

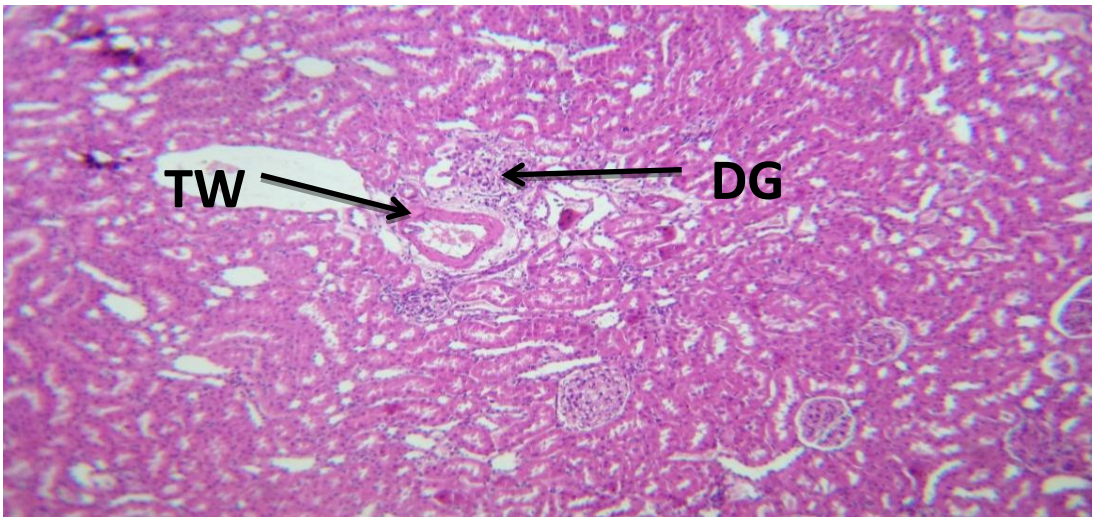

Figure 3: A cross section of the kidney of laboratory rats, group I (G1) exposed to ultraviolet rays, showing damage to glomeruli (DG), thickening of the walls of blood vessels (TW), color with hematoxylin and eosin H&E (40X).

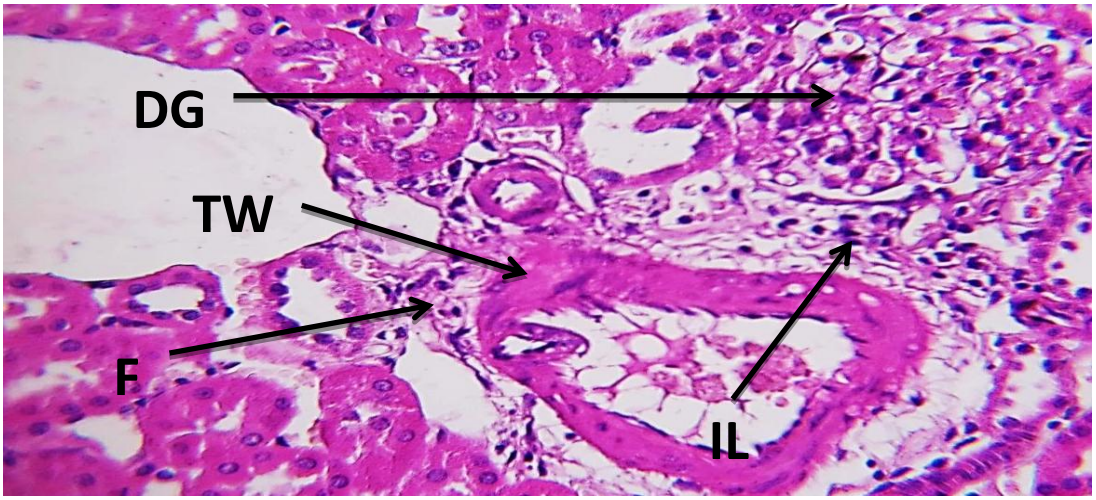

Figure 4: A cross section of the kidney of laboratory rats Group I (G1) exposed to UV light showing damage glomerulus (DG), vascular thickening (TW), infiltration of lymphocytes (IL), and fibroblast pooling (F) H&E Hematoxylin&Iosin Color (X100)

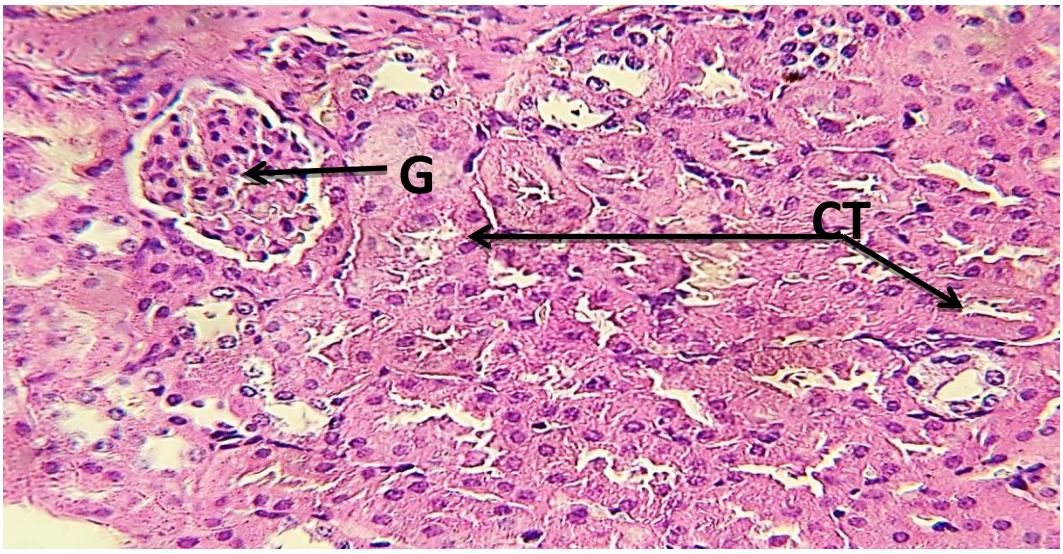

Figure 5: A cross section of the kidney of laboratory rats (group B) exposed to UV irradiation and dosed with active biomass solution EM-X showing the normal shape of glomerulus (G) and convoluted tubules (CT) color with H&E (40X).

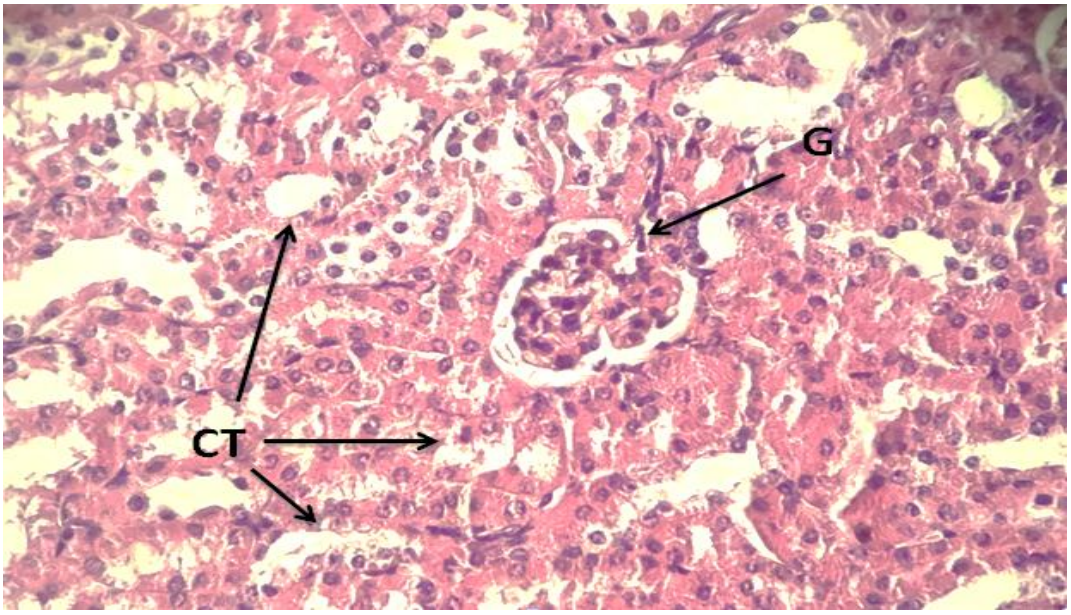

Figure 6: A cross section of the kidney of laboratory rats (group B) exposed to UV irradiation and dosed with active biomass solution EM-X. The normal shape of glomerulus (G) and convoluted tubules (CT) is shown in hematoxylin and eosin (H&E) (X100).

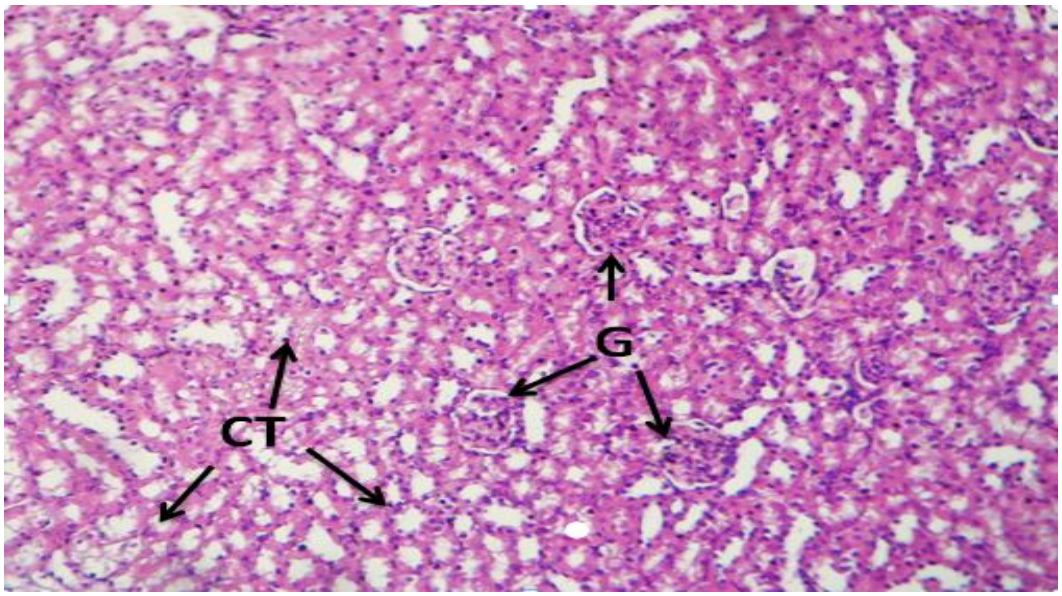

Figure 7: Cross-section of the kidney of laboratory rats of the control group(G3). Glomeruli (G) and convoluted tubules (CT) color with hematoxylin and eosin H&E (X40)

3. Discussion

This study was conducted to contribute to shedding light on the most important environmental problems that affect human health, as technical progress and urbanization are directly reflected on the environment through the increase in emissions and chemical fumes resulting from fuels and others such as (CFC, CFCl3, CF2Cl3), which cause a shortage in The thickness of the ozone layer (O3), which is the protective shield from ultraviolet rays, as it filters the largest percentage of this radiation, which directly affects living organisms [13].The kidney is one of the most important organs of the body due to the functions it performs.

It is the organ responsible for purifying and filtering the blood from toxins and waste products resulting from the metabolic process, as well as controlling the volume of fluids in the body and balancing the amount of electrical elements such as ions and salts, and the kidney is the second station after the liver In the process of converting vitamin D into the active form (D3) [14], vitamin D enters the body with food in the form of sterols and one hydroxyl group is added to it in the skin in the presence of ultraviolet rays, but the two forms of vitamin D present in the body so far are not sufficiently effective, Another hydroxyl group must be added to form

1.25cholecalciferol dihydroxy or 1.25 (HO)2 D3 or active vitamin D3, and this process takes place in the kidney tubules.

Which makes ultraviolet rays have a direct effect on the kidneys [16,15], which was confirmed by the histological examination of the kidneys of laboratory rats in the first group (G1) exposed only to ultraviolet rays, as the cross-section of the kidneys shows thickening in the walls of blood vessels with the accumulation of fibroblasts (Fig. 1) As the cross-section of the kidney appears in Figure (2), the damage to the glomeruli appears, thickening of the walls of blood vessels, infiltration of lymphocytes, and the accumulation of fibroblasts, and this is consistent with previous studies that indicate that vitamin D is a factor that is subject to change according to the amount of exposure to ultraviolet rays [18,17].

The presence of fibroblasts and the occurrence of thickenings in all cross-sections in the kidney of laboratory rats of the first group (G1 (Fig. (1,2,3,4)) is due to the high conversion rate of vitamin D3, which causes the accumulation of excessive collagen, a hallmark of fibrosis [19, 20].

The harmful effects of ultraviolet rays on the organs or systems of living organisms located indirectly under the skin.During exposure to radiation, free radicals are generated by the radioactive decomposition of water molecules.

These radicals interact with various biomolecules in cells and lead to changes in form and function and this is what was shown Histological sections in the first group (G1) of glomerular damage and necrosis, which caused infiltration of lymphocytes (Fig. (2,3,4) [22, 21]While the results of the histological study in the cross-sections of the kidneys of laboratory rats in the second group (G2) dosed with active mass solution with EM orally and exposed to ultraviolet rays on a daily basis showed the normal histological pattern similar to the cross sections in the kidney of rats of the control group, the studies confirmed the action of effective biomass EM for what It contains active ingredients represented by antioxidants, the most important of which are flavonoids (lycopene, uniquinone, ascorbic acid alpha-tocopherol).

In addition, other studies conducted on the active biomass solution EM confirmed the effective therapeutic role, through its role as an anti-inflammatory, and by inhibiting the production of inflammatory mediators, including cytokines and interleukins [23].The cross-section of the kidney of the second group of laboratory rats shows the normal tissue pattern (Fig. 5,6), and the effective biomass EM is an effective antioxidant, as it works to protect renal cells from the

oxidative stress caused by free radicals resulting from exposure to ultraviolet rays, and this What was confirmed by [24], and this may be attributed to the action of saponins, lycopene and flavonoids, which are present in the active biomass components, in the inhibitory effect of ultraviolet rays, as they make this substance a very effective antioxidant through its ability to increase the activity of enzymatic antioxidants inside the body of the organism. Including an increase in the activity of Superoxide Dismutase (SOD) and the capture of free radicals, which contributes to reducing lipid peroxidation and protecting cell membranes and organelles from oxidative damage, especially DNA, which makes the tissue appear almost normal, and its stimulating action has led to compensation for damaged cells from the effect of ultraviolet radiation [2426,25,].

References

1- Otero,S. ; Nunes, E.; Martinez, J.; Tomas R.; Arroniz M.,(2006). Effect of radiation on the cadmium and enhanced UV physiology and the concentration of UV absorbing compounds of the aquatic liverwort exsertifoliasubsp.photochemphotobiol. Sci.5: 766-769
2- Al-Fakji, TaghreedHazim Saber . (2003) A comparative microscopic study and the effect of some electromagnetic rays on the histological structure of the retina in two types of bony fish: Al-Sinak and Lakh Nakoura, Master’s thesis, College of Education, University of Mosul .
3- Klisch ,M, haeder, D,P(2001). Uv radiation on phytoplankton. Trends in photochemistry & Photobiology, Vol. 8, 137-143 .
4- Widmaier, Eric P.; Raff, Hershel; Strang, Kevin T. (2016). Vander's Human Physiology Mechanisms of Body Function. New York, NY: McGraw-Hill Education. pp. 14–15. ISBN 978-1-259-29409-9.
5- Furuta T, Maeda E, Akai H, Hanaoka S, Yoshioka N, Akahane M, Watadani T, Ohtomo K. (2009). Hepatic segments and vasculature: projecting CT anatomy onto angiograms. Radiographics. Nov;29(7):1-22. doi: 10.1148/rg.e37.
6- Chui, C.H. ; Hau, D.K.P. ; Lau, F.Y. ; Cheng, G.Y.M. ; Wong, R.S.M. ; Gambaria, R. ; Kok, S.H.L. ; Lai, K.B. ; Tang, J.C.O. ; Leung, T.W.T. ; Higa,T. ; Ke, B. ; Tang, J.C. ; Fong, D.W.F. and Chan, A.S.C. (2006)." Apoptotic potential of concentrated effective

microorganism fermentation extract on human cancer cells" . Int. J. Mol. Med., 17: 279-284.

7- Park K., Jeon S., Cho J., Park J., and Jang S.,(2011). Effective Microorganism substance (EM-S) Reduces development and aggravation of atopic dermatitis-like skin lesions in NC/Nga Mice. J.,KoreanSoc.,Appl., Biol.,Chem.,54(2):211-220.

8- Do, J., Seo, H., Hwang, J., Kim, J., and Nam, S.,(2007). Effective microorganism fermentation extract (EM-X) attenuates hyperreactivity and inflammation through selective inhibition of the TH2 response independently of antioxidant activity. Inter.J. of Molec. Med.20:631-635.

9- Abu-Yazed, E. (2007)."Effective microorganisms ".http://www.pal-stu.com/vb/showpost.php?p=29976&postcount=1.

10. R.H., Latteef (2001).The effects of ethyl alcohol on implantation and fecunding in mice , university of Tikrit , , Tikrit, Iraq

11. Ke, B., Xu Z., Ling, Y., Qiu, W., Higa, T., and Aruoma, I.,(2009). Modulation of experimental osteoporosis in rats by beverage effective microorganism-X(EM-X).Biomedicine and pharmacotherapy 63:114-119

12. Humason, G.L. (1967). Animal Tissue Techniques. 2nd.edn., W.H. Freeman Company, San Francisco.

13. Schulman, J.M.; Fisher, D.E. (**2009**),Indoor ultraviolet tanning and skin cancer: Health risks and opportunities. *Curr. Opin. Oncol. 21*, 144–149.

14. Sands JM, Verlander JW. (2005). Anatomy and physiology of the kidneys. In: Toxicology of the Kidney, 3rd ed (Tarloff JB, Lash LH, eds). CRC Press, Boca Raton, FL, 3-56.

15. Prosser DE, Jones G. (2004) Enzymes involved in the activation and inactivation of vitamin D. *Trends Biochem Sci.* ;29:664–73.

16. Henry HL. (2011)Regulation of vitamin D metabolism. *Best Pract Res ClinEndocrinolMetab.* ;25:531–41.

17. Du C, Yang S, Zhao X, Dong H(2017). Pathogenicroles of alterations in vitamin Dand vitamin D receptor in gastrictumorigenesis. Oncotarget.;25;8(17):29474.

18. Jäpelt RB, Jakobsen J. (2013)Vitamin D in plants:a review of occurrence, analysis, andbiosynthesis. Frontiers in plant science. ;13;4:136.

19. Abramovitch S, Dahan-Bachar L, Sharvit E, Weisman Y, Tov AB, Brazowski E, Reif S. (2011) . Vitamin D inhibits proliferation and profibrotic marker expression in hepatic stellate cells and decreases thioacetamide-induced liver fibrosis in rats. Gut.;60(12):1728–37.
20. Ding N, Ruth TY, Subramaniam N, Sherman MH, Wilson C, Rao R, Leblanc M, Coulter S, He M, Scott C. (2013) . A vitamin D receptor/SMAD genomic circuit gates hepatic fibrotic response. Cell.;153(3):601–13.
21. P. Verma, P. Sharma, J. Parmar, P. Sharma, A. Agrawal, P.K. (2011) Goyal Amelioration of radiation-induced hematological and biochemical alterations in Swiss albino mice by Panax ginseng extract Integrative Cancer Therapies, 10 (1), pp. 77-84, 10.1177.
22. Jagetia and Reddy, 2005 G.C. Jagetia, T.K. Reddy(2005) Modulation of radiation induced alteration in the antioxidant status of mice by naringin Life Sciences, 77, pp. 780-794, 10.1016/j.lfs.2005.01.015.
23. Ke, B., Liang, Y., Zhong, Z., Higa, T., and Aruoma, O.,(2005). Evaluation of the toxicity and safety of the antioxidant beverage effective microorganisms- X (EM-X) in animal models. Environmental Toxicology and Pharmacology 20:313-320.
24. Ali, L. H.(2013). Astudy of Histological and Physiological Effects of Cymbopogoncitratus Oil and Effective Microorganism EM-X on Growth Inhibiting Of Cancer Cells Induced in Male of Albino Rats , university of Tikrit , Tikrit, Iraq.
25. Park K., Jeon S., Cho J., Park J., and Jang S.,(2011). Effective Microorganism substance (EM-S) Reduces development and aggravation of atopic dermatitis-like skin lesions in NC/Nga Mice. J.,KoreanSoc.,Appl., Biol.,Chem.,54(2):211-220.